

Total Knee Arthroplasty in a Patient with Bilateral Fused Hip due to Seronegative Arthritis: A Case Report

TUSHAR CHAUDHARI¹, SWAROOP SOLUNKE², ABHISHEK NAIR³, PRATIK GUNDECHA⁴



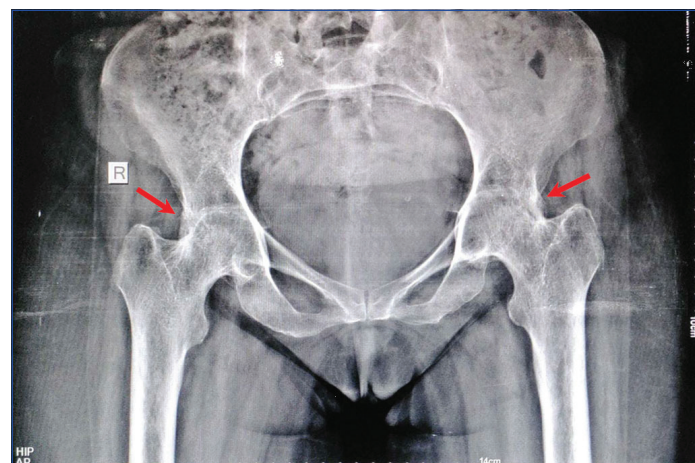
ABSTRACT

Degenerative changes in other joints secondary to hip fusion occur due to changes in the relative biomechanical forces acting on those joints. At present, there are no standard protocols to aid the decision-making process of joint replacement surgery in patients with hip fusion due to secondary arthritis causes. Each patient requires tailored management planned by the surgeon to optimise treatment plan and achieve the highest degree of functional improvement. Total Knee Arthroplasty (TKA) is a well-documented, common, and cost-effective procedure in the management of morbidities associated with joint degeneration due to wear and tear of the cartilage. TKA in patients with hip fusion is relatively rare, and there are few case reports and studies indicating a standardised approach and treatment protocols for the same. In this case report, TKA due to symptomatic knee arthritis in a patient with a 15-year history of spontaneous bilateral hip fusion due to seronegative arthritis is discussed. Postoperatively, the patient's condition was stable, with good Range Of Motion (ROM) at the knee and without aseptic features as determined by recent radiologic investigations.

Keywords: Ankylosing spondylitis, Hip arthritis, Total knee replacement

CASE REPORT

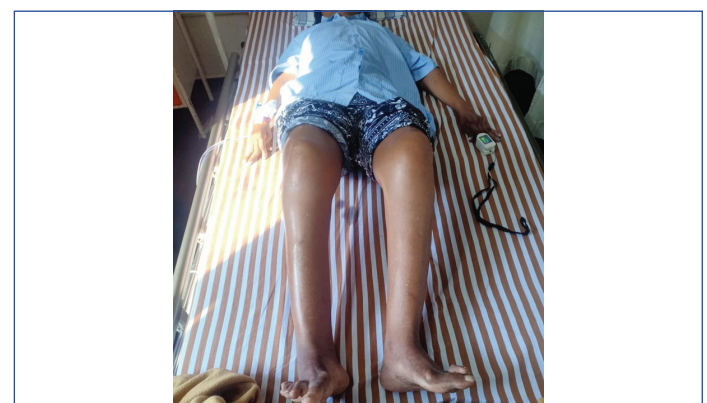A 53-year-old woman came to the Out-Patient Department (OPD) with complaints of pain in her left knee, which had been of gradual and progressive nature over the course of two years. Initially, the patient felt that the pain was manageable; however, due to increased aggravation, she decided to visit a physician to alleviate her symptoms. The patient said that she did not experience any trauma prior to the onset of her symptoms. She was a housewife and has noticed increased difficulty in moving about in the house, climbing stairs, as well as performing household chores. Her pain score was eight out of 10 on the visual analogue scale. The patient also stated that she feels a locking sensation in her left knee, which was aggravated on movement and weight-bearing, causing her gait to be antalgic in nature. The pain was relieved on rest and worsens throughout the day with activity. Described as 'dull' in nature and was localised to the medial aspect of the left knee. She also walks with a limp developed because of bilateral spontaneous hip fusion secondary to seronegative arthritis, which was diagnosed 15 years back for which she was not receiving any medical treatment or physiotherapy [Table/Fig-1].



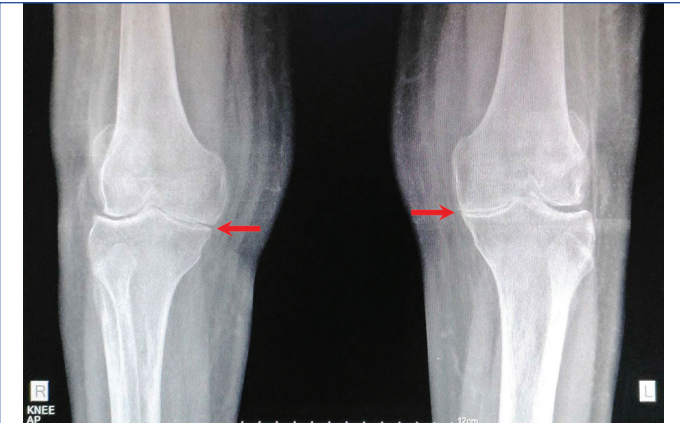
[Table/Fig-1]: Preoperative plain radiograph Pelvis with Both Hips (PBH)- Antero-posterior (AP) view showing bilateral arthritic and degenerative changes of the hip with bony ankylosis.

On inspection, the patient's hip joint was in flexion, abduction, and external rotation with an inability to place the joint in a neutral position. A history of bilateral hip fusion posed a difficulty in attempting the Thomas test to estimate the degree of hip deformity. The patient also had a shortened left limb with a true limb length discrepancy greater than three cm (about 1.18 inches). The patient's spine was in hyperlordosis to extend her hip. As a result, the patient was placed in the prone position on the examination bed to straighten the lordosis, followed by stabilisation with the palm and extension until the lordosis was apparent again. The angle between the body and the thigh was taken as the flexion deformity at the hip and was found to be 30°. The ROM appeared to be severely restricted in all directions, more predominant in the sagittal plane (flexion-extension) and axial plane (internal rotation-external rotation), suggesting ankylosis due to severely damaging seronegative arthritis.

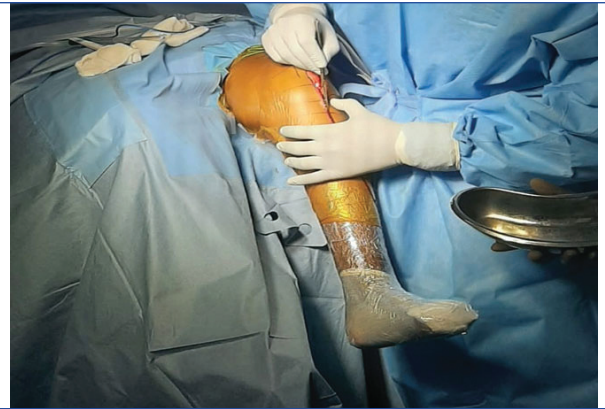The attitude of the patient's knee joint was found to be in flexion, with difficulty in complete extension of the knee [Table/Fig-2]. A swelling approximately one cm (about 0.39 inches) × two cm (about 0.79 inches) was appreciated over the medial aspect of the left knee, which was tender and bony to touch. Crepitus was felt throughout the ROM. Marked degeneration of the knee joint bilaterally with narrowing of joint margins was observed in the X-ray [Table/Fig-3].



[Table/Fig-2]: Preoperative physical examination of the patient displaying fixed hip and knee flexion deformity bilaterally at 30°. Marked deformities associated with arthritic changes can also be observed at the hands and feet bilaterally.

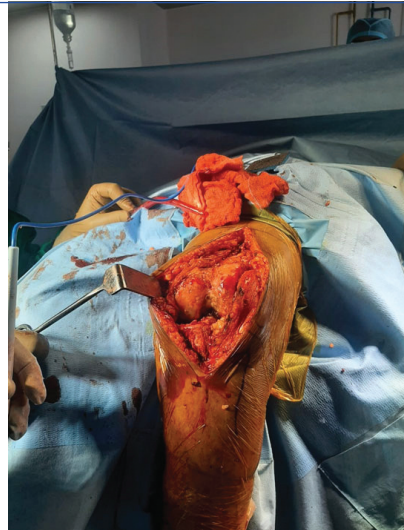

[Table/Fig-3]: Preoperative plain radiograph of bilateral knee AP view displaying marked degeneration of the knee joint bilaterally with narrowing of joint margins.

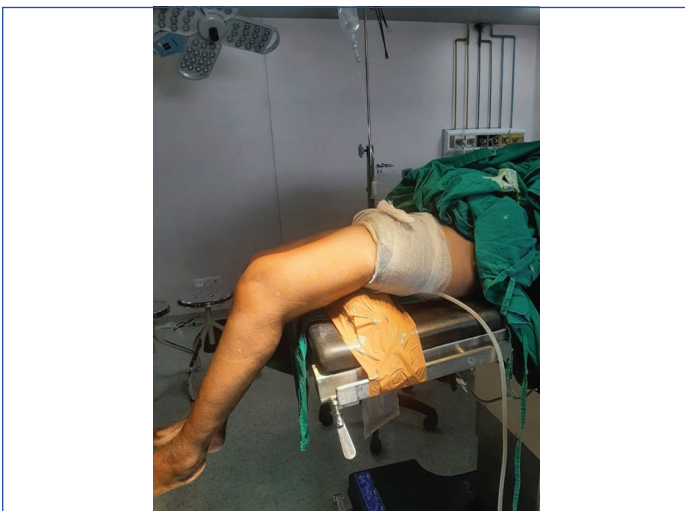

[Table/Fig-5]: An incision was made over the anterior aspect of the left knee.

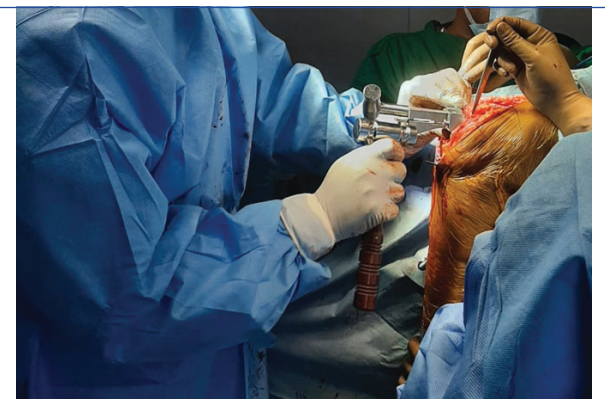The patient was diagnosed with bilateral knee osteoarthritis with maximum pain in her left knee joint; hence, TKA of the left knee as a definitive treatment was planned. The patient was positioned supine on the table, allowing both lower extremities to hang over the table's edge. A bolster was placed under the ipsilateral thigh and buttock. The table was elevated to its maximum height level above the ground, with the head in a low position. This positioning was essential due to the fusion of both hips. Scrubbing and painting of both lower limbs were done. Following this, a midline incision over the anterior aspect of the left knee was taken followed by a parapatellar approach, and the knee joint was fully exposed [Table/Fig-4-8]. Upon exposure of the knee joint, extensive damage of cartilage and meniscus was noted. Adequate soft tissue removal was done and healthy tissue was conserved. Initially, distal femur and proximal tibia cuts were taken using the zig provided with the instrument set. Then, the extension gap was determined. Femoral sizing and cuts were taken to decide the flexion gap. Finally, tibial keel preparation was done followed by adequate release of the posterior capsule. Trial implants were tried to check the stability of the knee, which was found to be stable. Full ROM of the knee joint was achieved and confirmed. Hence, cementing of the final implant was done followed by closure done in layers.



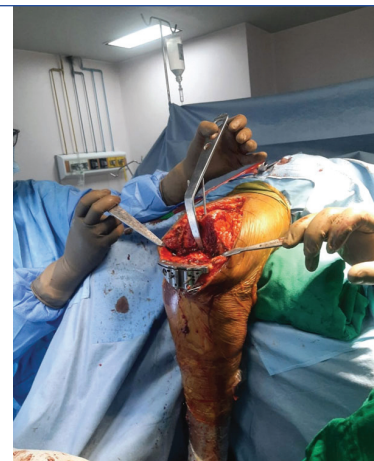[Table/Fig-6]: The picture displays the initial visualisation of the knee after incision was taken followed by superficial and deep dissection and tendon manipulation.



[Table/Fig-4]: A bolster was placed under the left thigh and buttock to allow a greater degree of flexion during the Total Knee Arthroplasty (TKA) in headlow position.

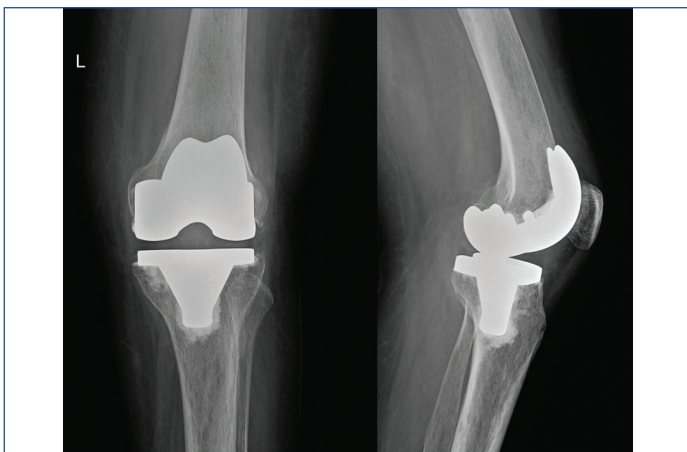


[Table/Fig-7]: The figure depicts femur preparation.



[Table/Fig-8]: A flexion of 90° was achieved followed by reduction of osteophytes and placement of the knee prosthesis. The figure depicts tibial preparation.

The patient's recovery in the ward postsurgery was uneventful. Radiologically, proper placement of the prosthesis and a TKA without any abnormalities was observed in the X-ray [Table/Fig-9]. She was able to ambulate on the third postoperative day and was discharged after six days. At six weeks after surgery, she achieved good ambulation, and the ROM in the left knee was from 0° to 95°. At six months, the patient had sufficient improvement in her quality of life, movement, and activities of daily living. Her ROM was 0-100 degrees.



[Table/Fig-9]: Postoperative plain radiograph of the left knee from an AP-Lateral view displaying proper placement of the prosthesis and a TKA without any abnormalities.

DISCUSSION

There are multiple approaches towards the management of degenerative changes of the knee which occur due to an increase in the magnitude of biomechanical forces successive to hip fusion. Possible surgical interventions include performing TKA alone, conversion from hip fusion to total hip arthroplasty followed by a TKA, or conversion of the fused hip to total hip arthroplasty without a TKA. TKA is advised for hips that are fused with 20 to 30° of flexion, 5° of adduction, 5 to 10° of external rotation, and a limb length difference of no more than 2 cm [1,2]. Cases of TKA following both spontaneous and surgical hip fusion have been reported from different countries [2-7].

Studies have also claimed that in patients with hip ankylosis, a total hip arthroplasty followed by a TKA may provide a greater degree of improvement compared to only a TKA. Owing to improper alignment of the fused hip, correct positioning of the prosthetic material during TKA may be inadequate, leading to loosening of the prosthetic material, which could require revisional surgery [8,9]. The stiff hip would also hinder the rehabilitation process due to increased tension across the muscles crossing both the hip and knee. This could also lead to difficulty in performing the TKA as the knee will not permit the degree of flexion required for placement of the required components, leading to a change in the standard surgical technique. It has been reported that in cases of hip fusion, total hip arthroplasty before TKA can reduce the stress on the knee implant after replacement [9]. In contrast, for index patient, a decision was not made to convert the fused hip to a mobile one prior to TKA. The patient requested no surgical intervention in her bilateral hip fusion as she had a fixed, stable, and painless hip, which is one of the common reasons mentioned in past studies as well [10].

Factoring in the expectations of the patients is important in a patient-centered approach. In index patient, a bolster was placed under the ipsilateral thigh and buttock, elevating the ankylosed joint which granted a greater degree of flexion (up to 100°) during the operation. Koo K et al., placed a sandbag under the ipsilateral buttock, which was observed to have caused a knee tilt towards the opposite limb. In this situation, Koo K et al., tilted the operating table by 20° for compensation [8]. Hanging the leg over the side of the operating table could also be considered if a greater degree of knee flexion is needed during the operation [9].

While in present case, the procedure gave the patient a postoperative ROM from zero to 100° by six months, a previous case reported an ROM of up to 84° [9]. Encinas-Ullan CA et al., reported an ROM of up to 115° in one of their patients [4]. However, the duration of follow-up was longer in the other reports, ranging from 3 to 7.8 years [4,9].

CONCLUSION(S)

A case of TKA in a patient with a past medical history of bilateral spontaneous hip fusion brought on by years of seronegative arthritis is reported. The patient had a good immediate and short-term outcome. In a situation where a TKA is preferred, modifications such as the use of a bolster, along with other approaches discussed in previous reports, should suffice. Further long-term follow-up and outcome assessment of the patient are required to determine the efficacy of the procedure.

REFERENCES

- [1] Konarski W, Poboży T, Hordowicz M. Hip fusion takedown with total knee and hip arthroplasty in a patient with end-stage chronic kidney disease- A case report and narrative literature review. *Orthop Rev (Pavia)*. 2022;14(3):35452.
- [2] Poboży T, Konarski W, Hordowicz M. Hip fusion takedown with subsequent hip and knee arthroplasty. Case study. *Ortop Traumatol Rehabil*. 2020;22(6):475-86.
- [3] Ashkenazi I, Habibi A, Schwarzkopf R. Total knee arthroplasty in a patient with ipsilateral painless hip arthrodesis: Technical surgical tips and a novel method for intraoperative navigation-assisted planning. *Surg Technol Int*. 2023;42:sti42/1664.
- [4] Encinas-Ullán CA, Gómez-Cardero P, Rodríguez-Merchán EC. Total knee arthroplasty in patients with prior ipsilateral hip fusion: A surgical technique. *HSS J*. 2022;18(1):175-81.
- [5] Fukuhara D, Inoue H, Nakagawa S, Arai Y, Takahashi K. Tibial condyle valgus osteotomy for ipsilateral knee osteoarthritis after hip arthrodesis. *Case Rep Orthop*. 2021;2021:6443618.
- [6] Samborski SA, Quinzi D, Balkissoon R. Total knee arthroplasty with prior ipsilateral hip arthrodesis. *Arthroplasty Today*. 2020;6(4):830-34.
- [7] Tang X, Yan Z, Wang W, Liu T. Total knee arthroplasty in a patient with ipsilateral hip ankylosis: A case report. *Medicine (Baltimore)*. 2019;98(36):e16889.
- [8] Koo K, Pang KC, Wang W. Total knee arthroplasty in a patient with a fused ipsilateral hip. *J Orthop Surg Res*. 2015;10:127.
- [9] Romness DW, Morrey BF. Total knee arthroplasty in patients with prior ipsilateral hip fusion. *J Arthroplasty*. 1992;7(1):63-70.
- [10] Goodman SB, Huddleston JI 3rd, Hur D, Song SJ. Total knee arthroplasty in patients with ipsilateral fused hip: A technical note. *Clin Orthop Surg*. 2014;6(4):476-79.

PARTICULARS OF CONTRIBUTORS:

1. Assistant Professor, Department of Orthopaedics, Dr. D.Y. Patil Medical College, Hospital and Research Centre, Pimpri, Pune, Maharashtra, India.
2. Associate Professor, Department of Orthopaedics, Dr. D.Y. Patil Medical College, Hospital and Research Centre, Pimpri, Pune, Maharashtra, India.
3. Assistant Professor, Department of Orthopaedics, Dr. D.Y. Patil Medical College, Hospital and Research Centre, Pimpri, Pune, Maharashtra, India.
4. Resident, Department of Orthopaedics, Dr. D.Y. Patil Medical College, Hospital and Research Centre, Pimpri, Pune, Maharashtra, India.

NAME, ADDRESS, E-MAIL ID OF THE CORRESPONDING AUTHOR:

Dr. Pratik Gundecha,
Dr. D.Y. Patil Medical College, Hospital and Research Centre,
Dr. D.Y. Patil Vidyapeeth, Pimpri, Pune-411018, Maharashtra, India.
E-mail: pratik.gundecha789@gmail.com

AUTHOR DECLARATION:

- Financial or Other Competing Interests: None
- Was informed consent obtained from the subjects involved in the study? Yes
- For any images presented appropriate consent has been obtained from the subjects. Yes

PLAGIARISM CHECKING METHODS: [Jan H et al.]

- Plagiarism X-checker: Dec 25, 2023
- Manual Googling: Feb 02, 2024
- iThenticate Software: Feb 08, 2024 (14%)

ETYMOLOGY: Author Origin

EMENDATIONS: 5

Date of Submission: **Dec 25, 2023**

Date of Peer Review: **Jan 24, 2024**

Date of Acceptance: **Feb 10, 2024**

Date of Publishing: **Mar 01, 2024**